

Difficult Case 2

Sanjay Bhagani

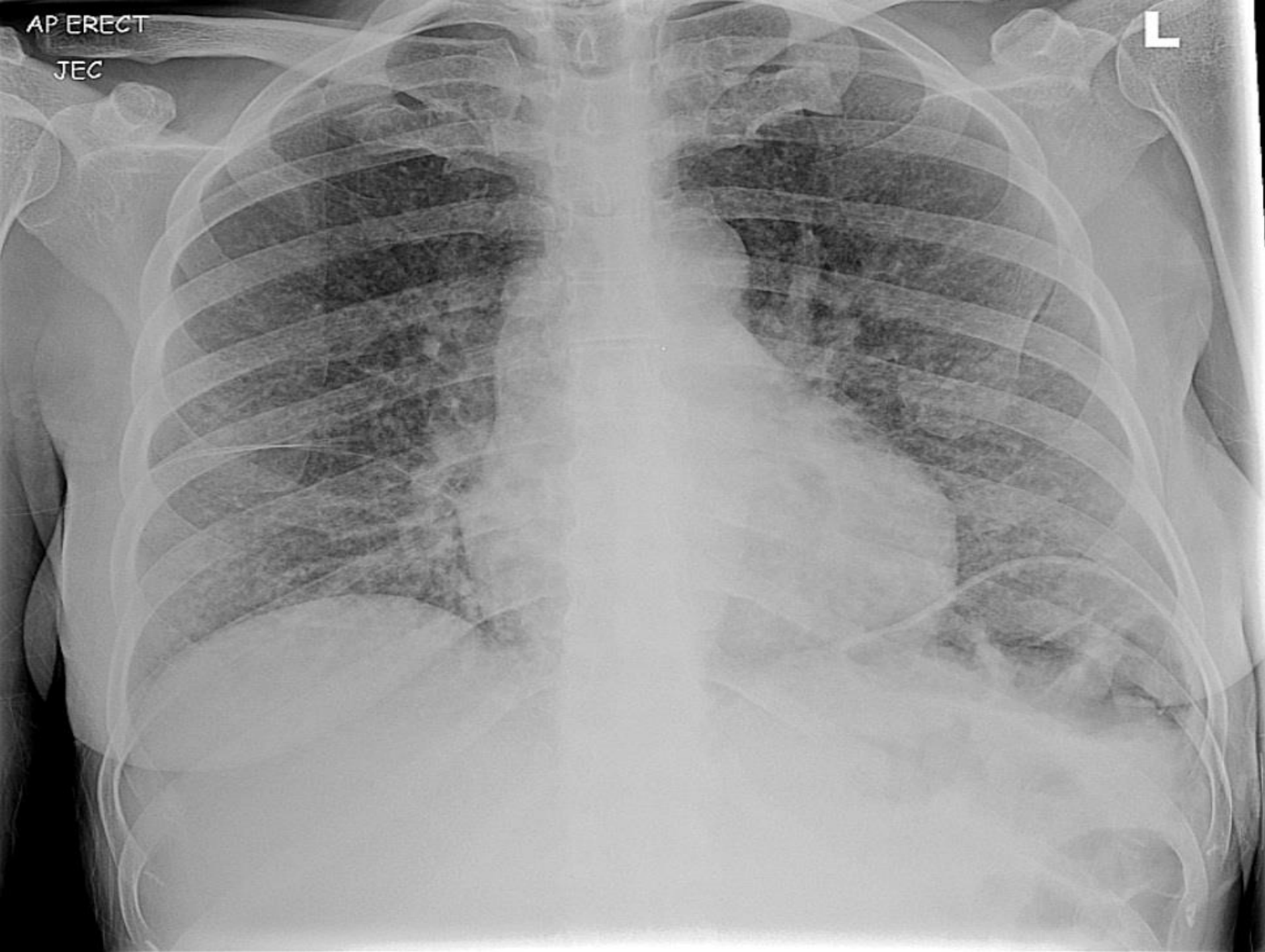RFH/UCL

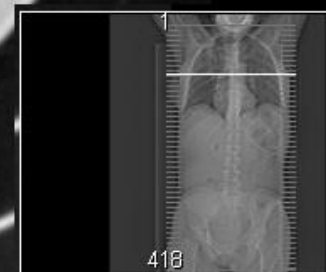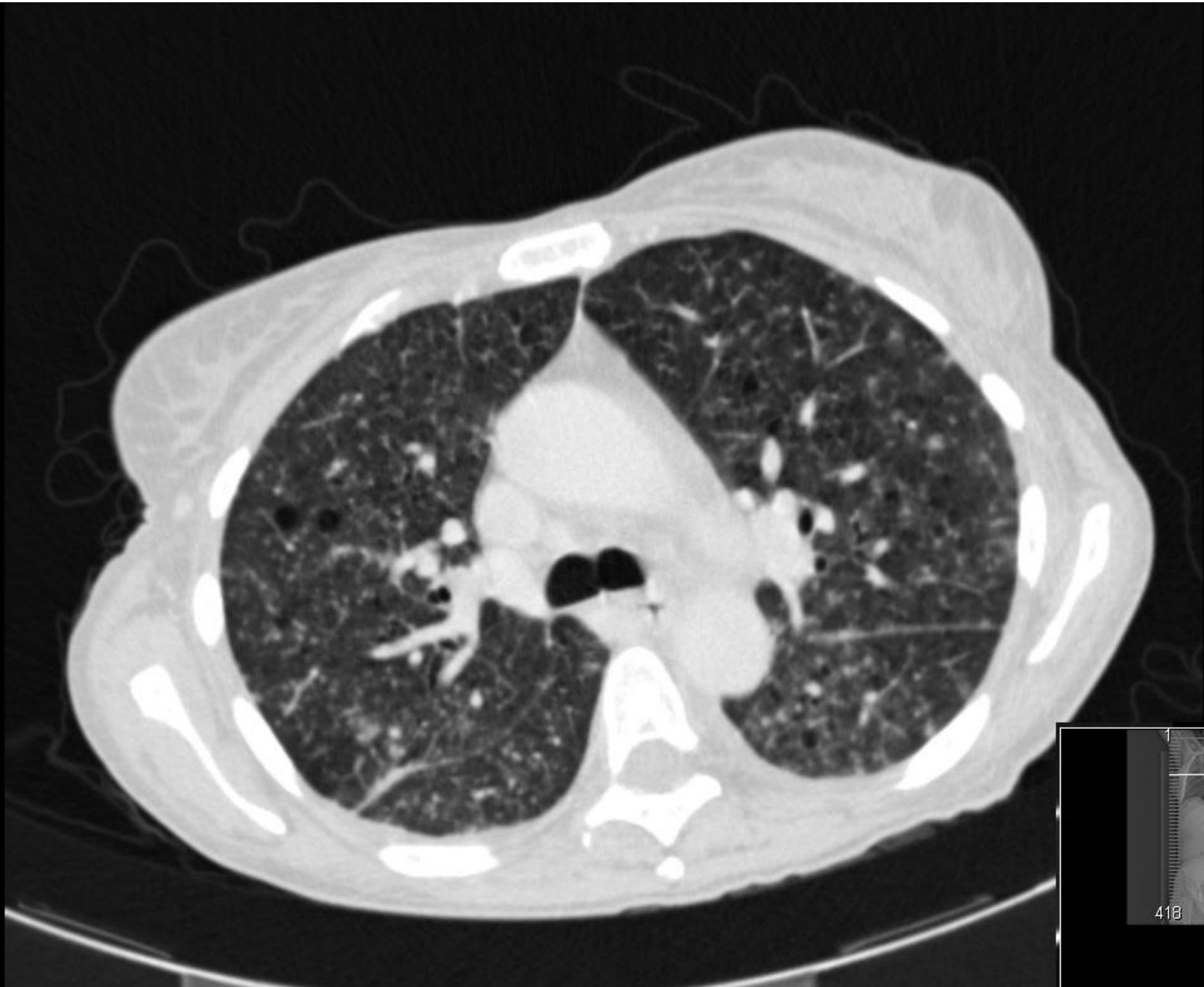London

- 43 year old Ugandan lady
- UK for 10yrs, one stable partner
- 4 months of fever, weight loss, night sweats, intermittent diarrhoea and abdominal pain and more recently (4 weeks) cough and shortness of breath
- New diagnosis of HIV, CD4 122 viral load 28000 c/ml
- HBV/HCV/Syphilis negative
- Serum CrAg negative

AP ERECT
JEC

L



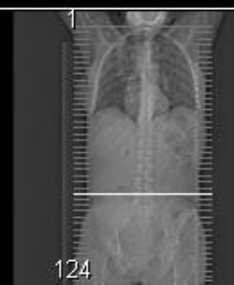
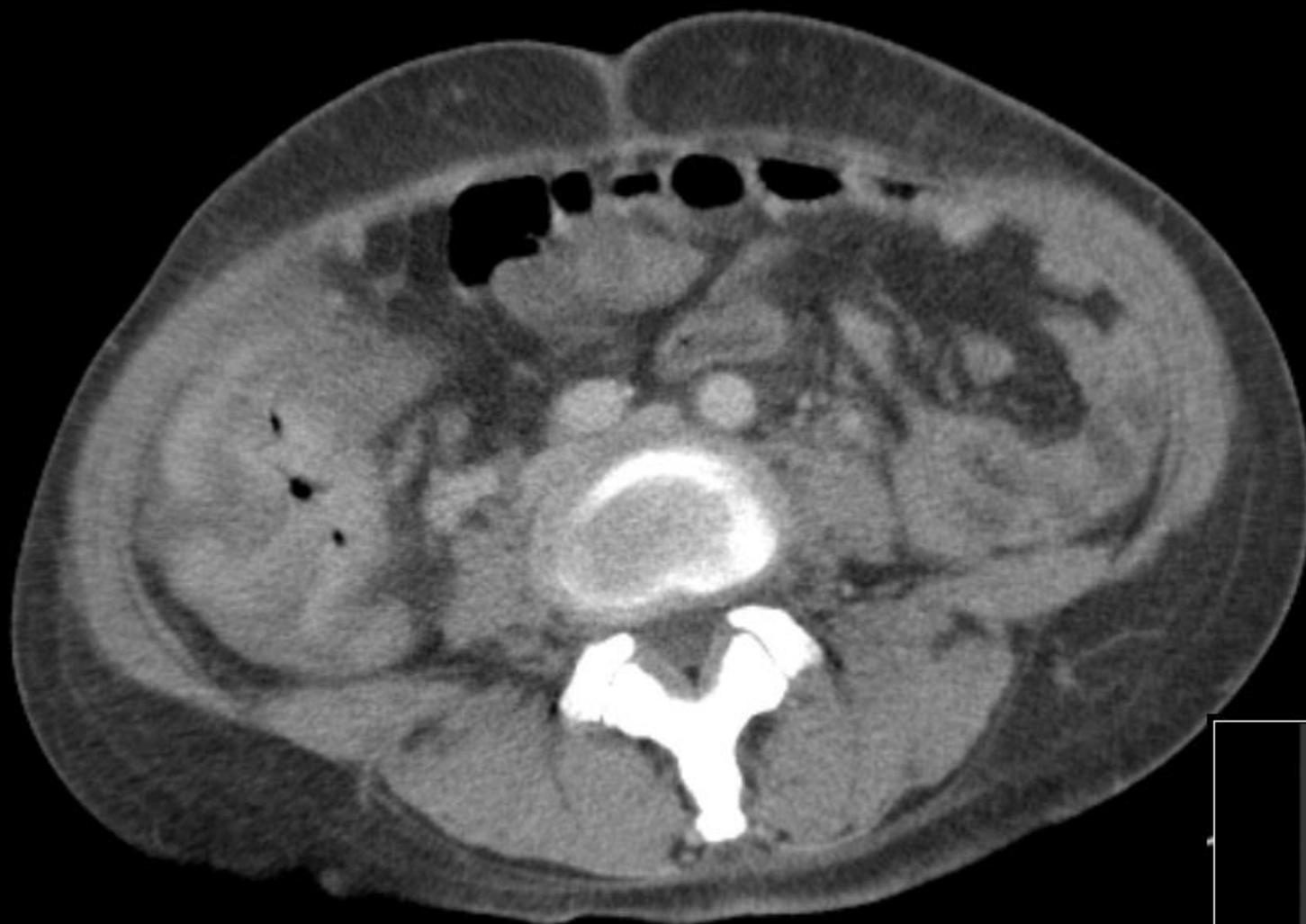
418

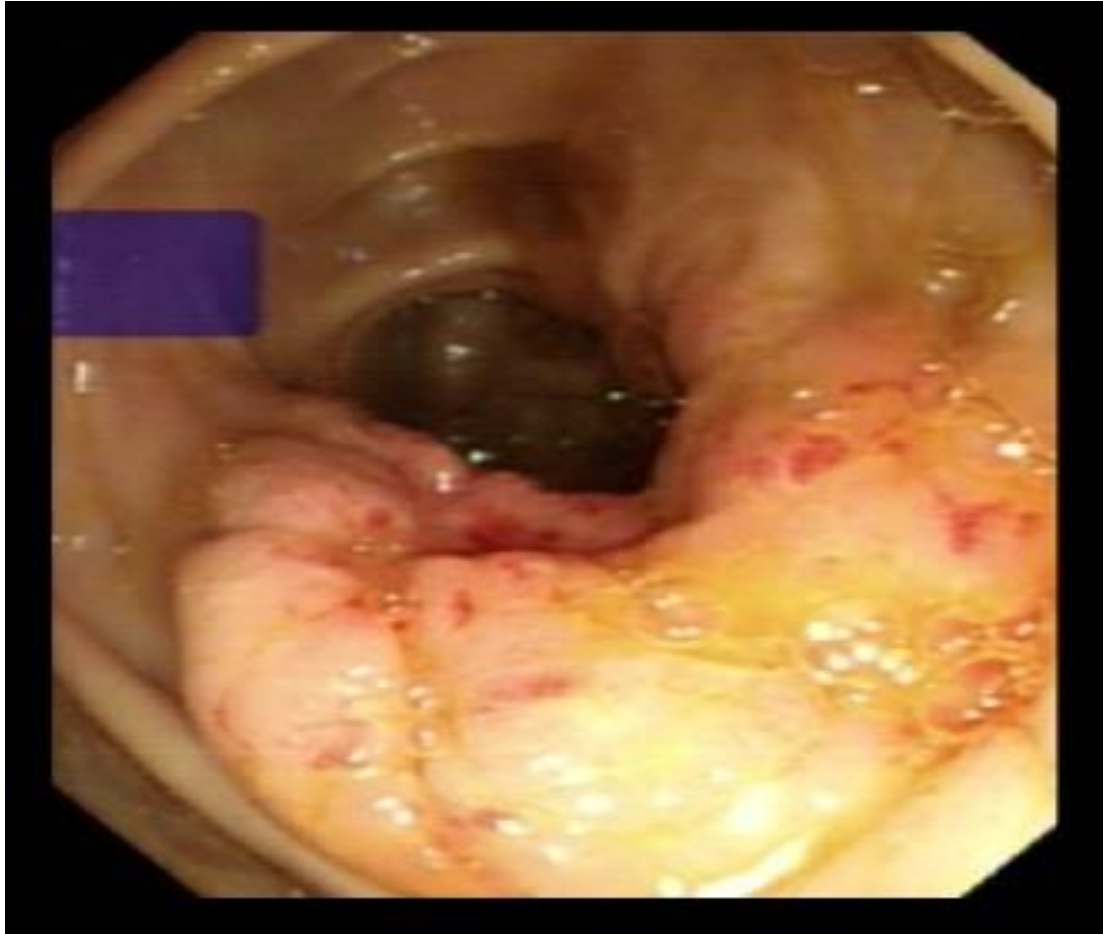- Broncho-alveolar lavage performed
- PJP confirmed
- ZN stain and TB-PCR negative
- Multiple stool specimens – negative microscopy
- Started on high-dose co-trimoxazole and steroids
- Transferred to our unit

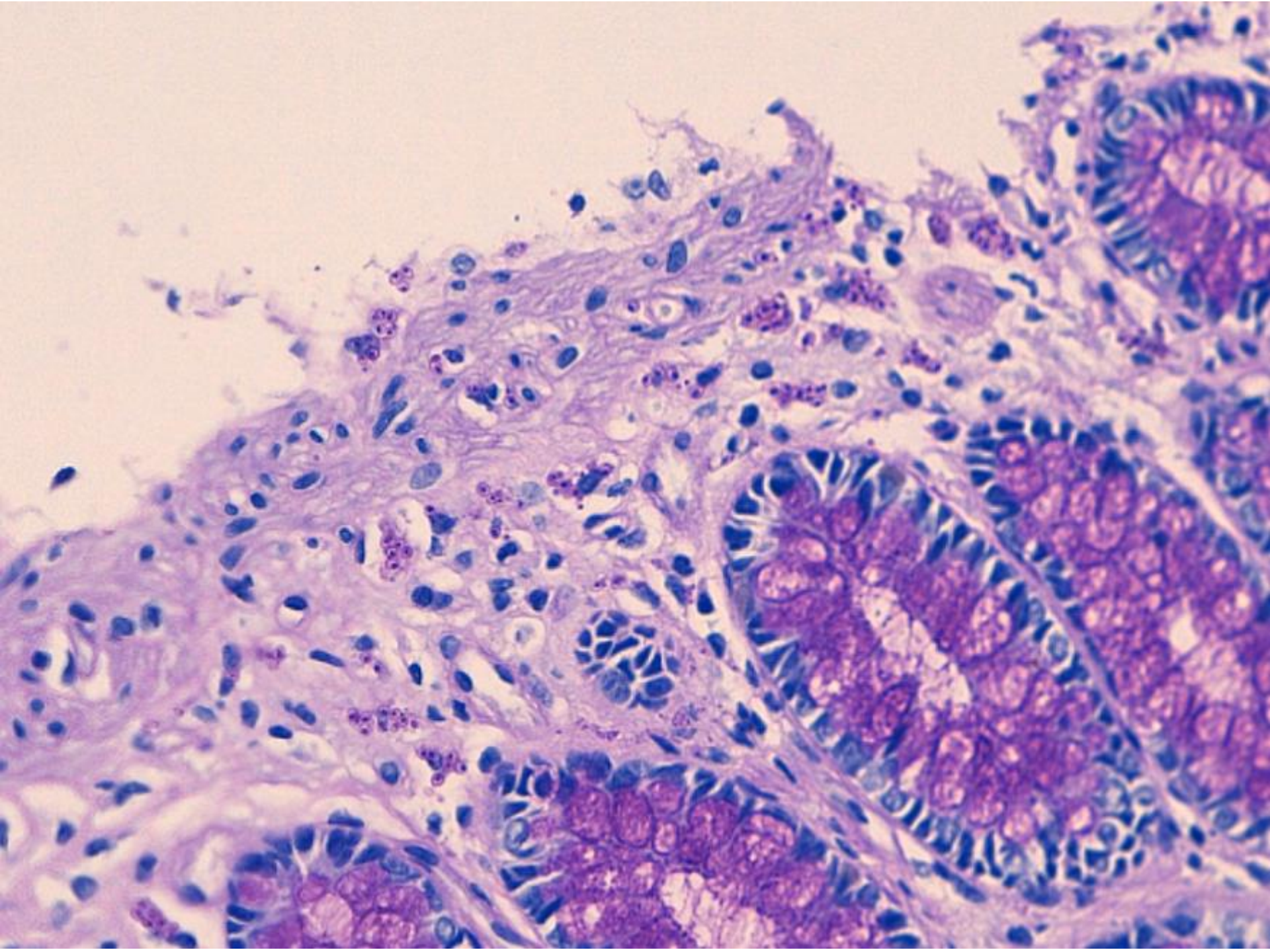
Summary on transfer...

- Advanced HIV disease – CD4 ~120
- Non-specific - but weight loss, abdominal and respiratory symptoms
- Diagnosis of PCP confirmed
- Do we want to do anything else?



What else is now in the differential diagnosis and what other tests?

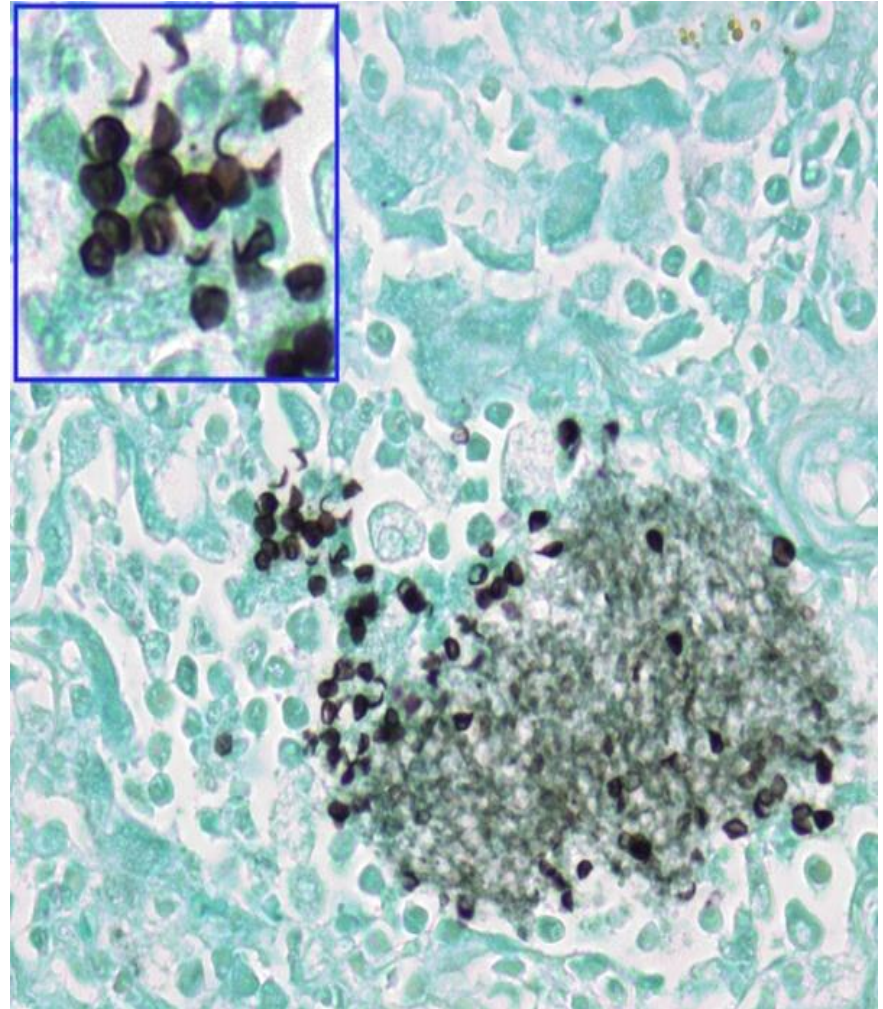
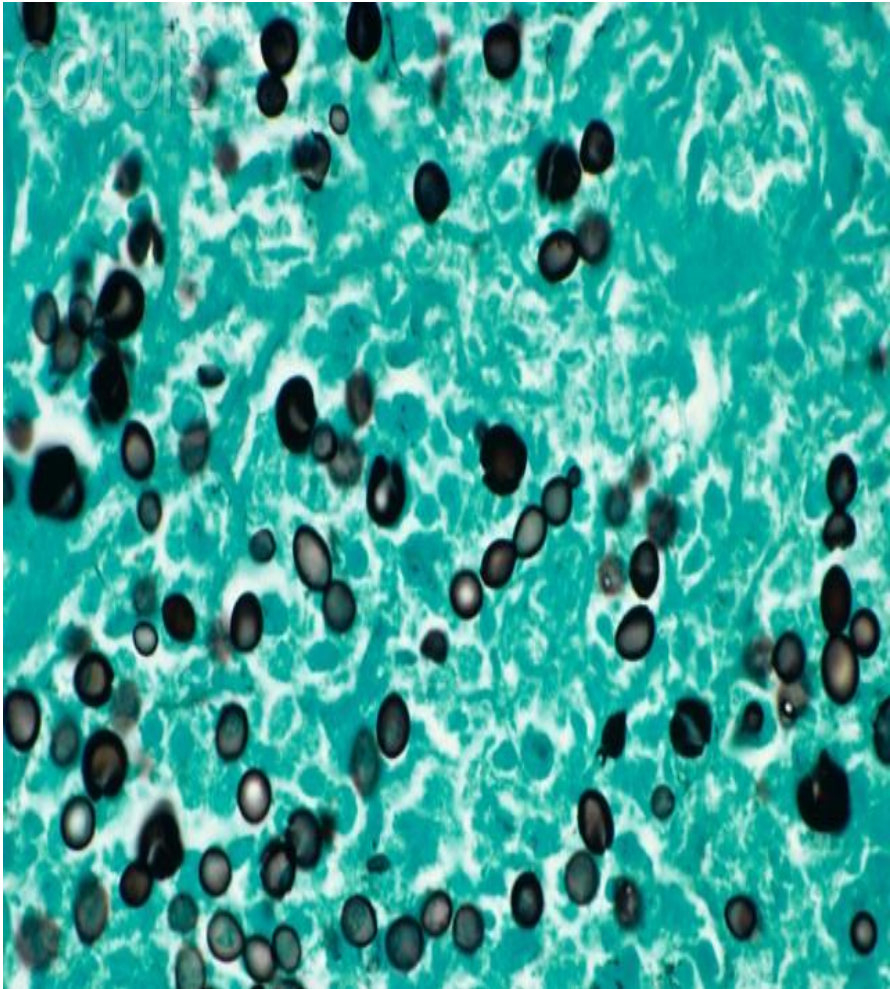



So do we have two diagnoses?

- PCP
- Histoplasmosis

Histoplasma vs. Pneumocystis



Occam's Razor

- one should not increase, beyond what is necessary, the number of entities required to explain anything