

# HIV/AIDS in Japan

## From one physician's perspective



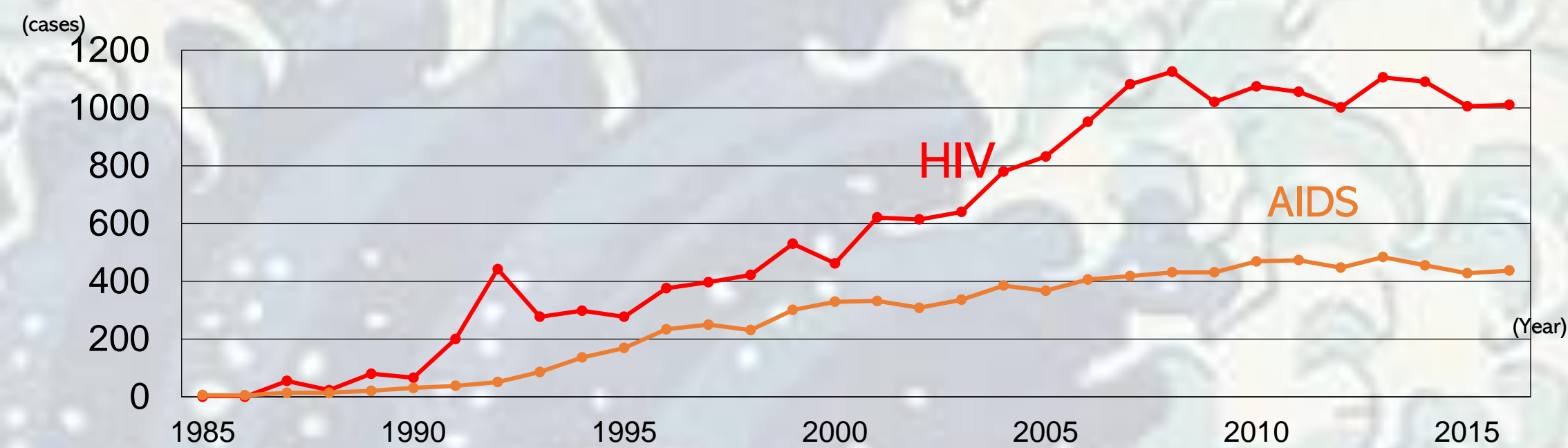
Takashi Muramatsu, Department of Laboratory Medicine, Tokyo Medical University Hospital

### Basic demographic

Land area: 377,899 sq km  
Population: 126 million (2016; UN)  
Tokyo (capital; 23 central wards): 9.1 million

### HIV/AIDS epidemic in Japan

The annual reported cases of newly diagnosed HIV/AIDS



**26,670** people living with HIV

**<0.1%** adult HIV prevalence

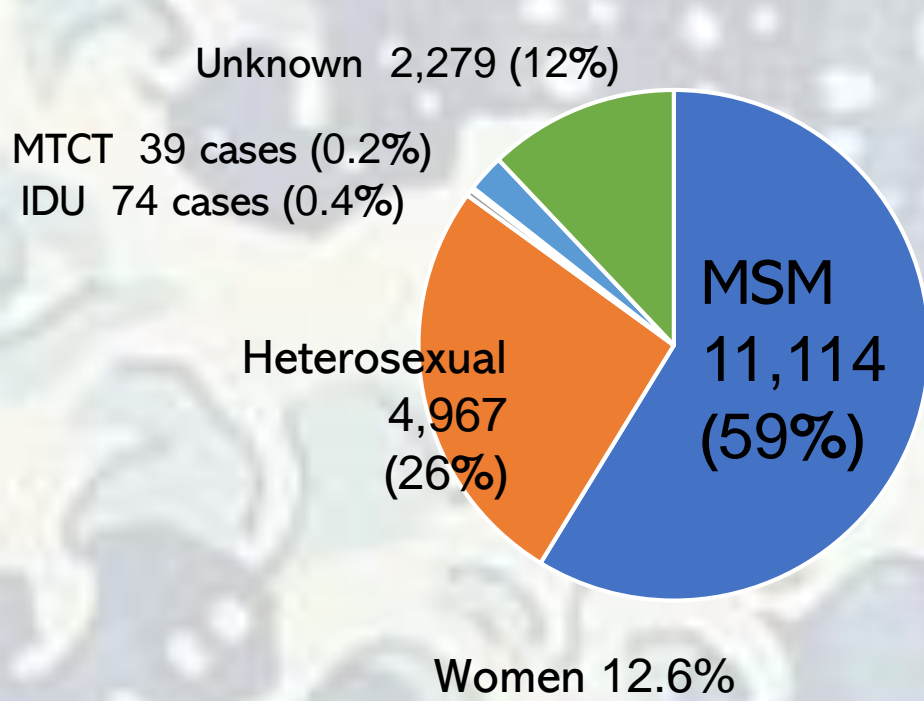
**1,011** new infections in 2016

**14** AIDS-related deaths in 2015

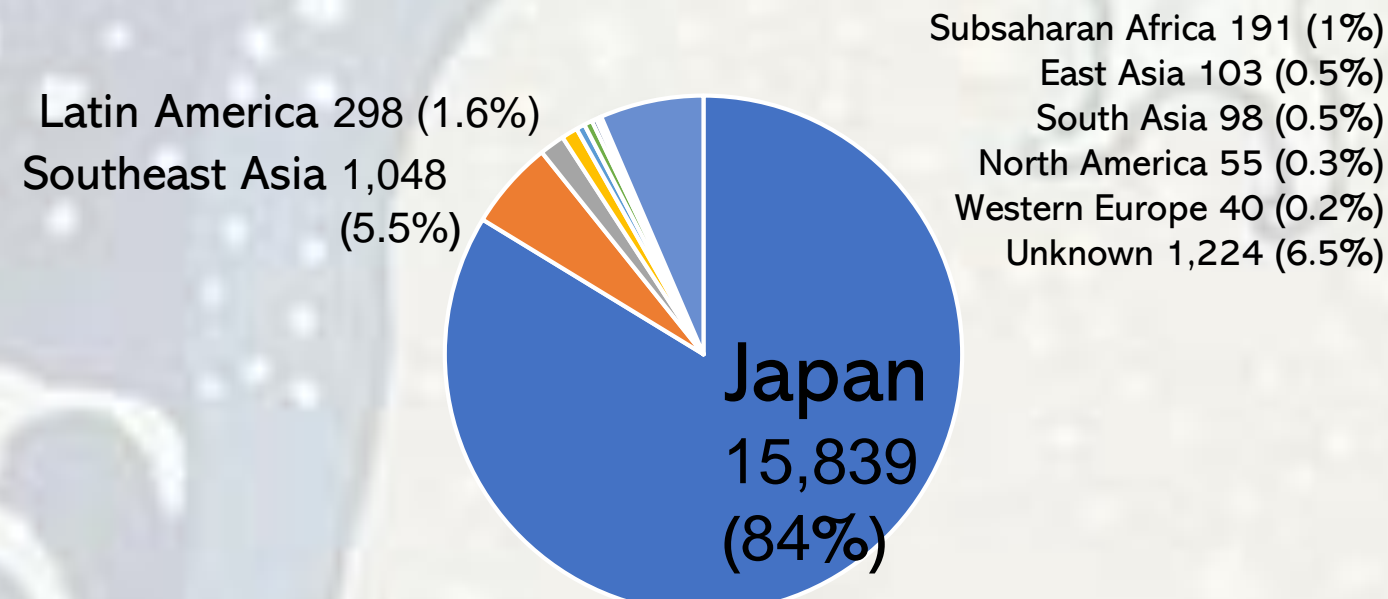
WHO's cascade: **86-83-99**

UNAIDS Fact sheet, *PLoS ONE* 12(3): e0174360, 2017

### The route of transmission



### Nationalities

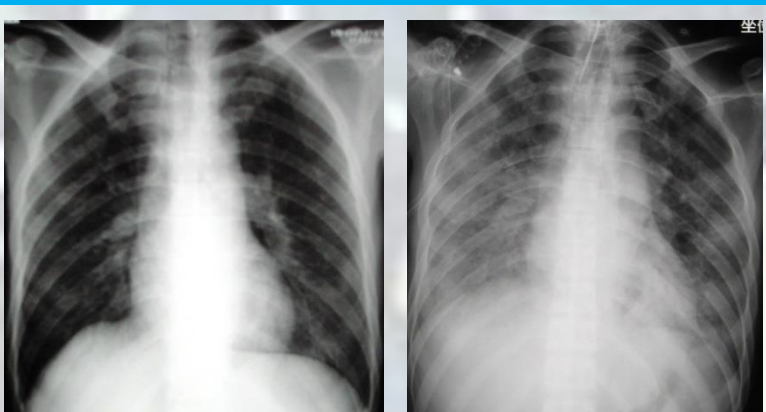


### Problems we face right now

- ✓ Late diagnosis, advanced AIDS cases
- ✓ Stigma
- ✓ PrEP is not available
- ✓ Coinfections (STIs, hepatitis)
- ✓ Age-related comorbidities
- ✓ Malignancy

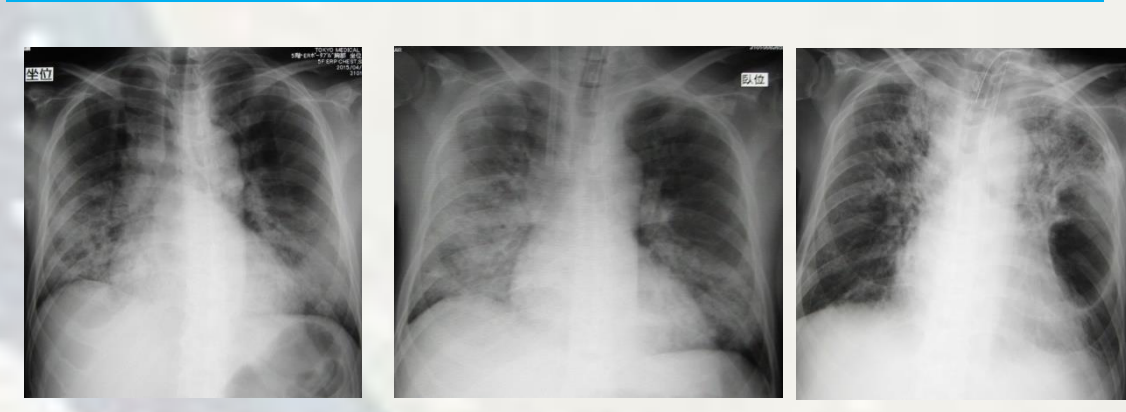
### Obstacles and challenges

#### Case 1 Pneumocystis pneumonia



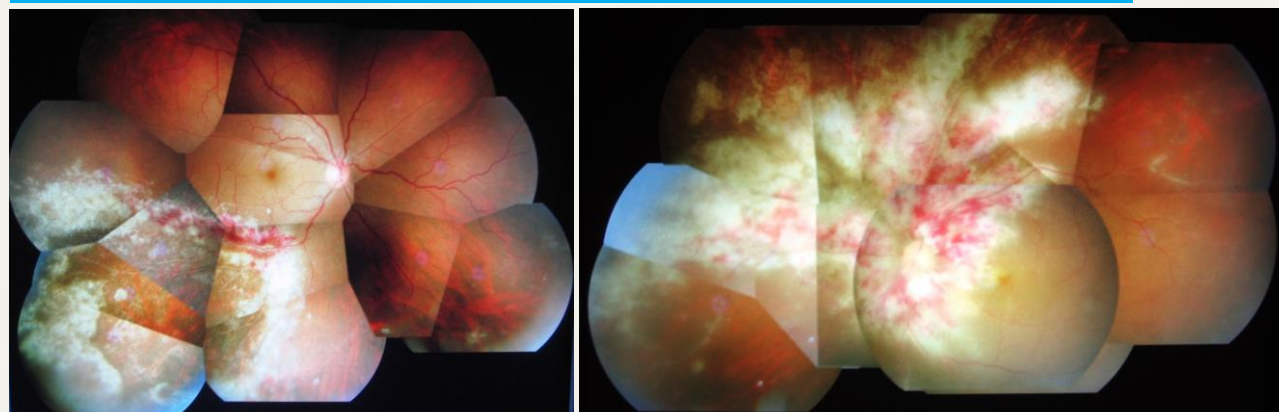47 yo man, CD4 60.4/ $\mu$ L, LD 631, A-aDO<sub>2</sub> 203.9  
day8 intubation, mechanical ventilation  
day 13 died

#### Case 2 Pneumocystis pneumonia



41 yo man, CD4 5/ $\mu$ L, LD 1,511 IU/L, A-aDO<sub>2</sub> 346.4  
day 5-23 ECMO (extracorporeal membrane oxygenation)  
day 36 ART start  
day 180 discharge from the ward

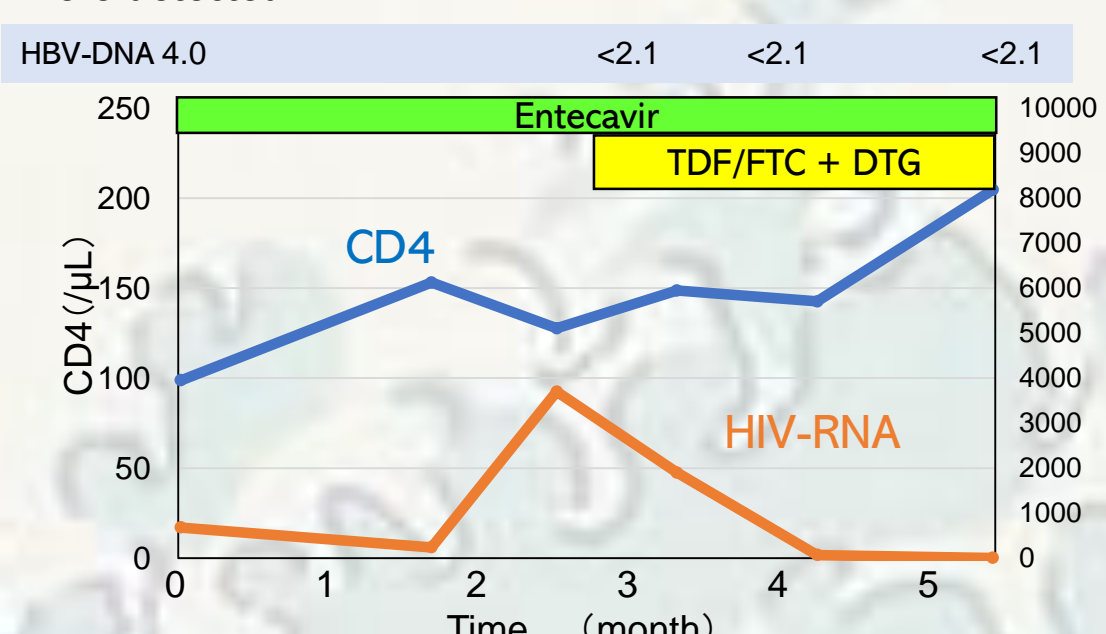
#### Case 3 Cytomegalovirus retinitis



27 yo man  
CD4 58.3/ $\mu$ L, HIV-RNA 2,700,000 copies/mL  
He refused to start antiretroviral therapy, because he wanted to prioritize herbal medicine but eventually developed serious CMV retinitis

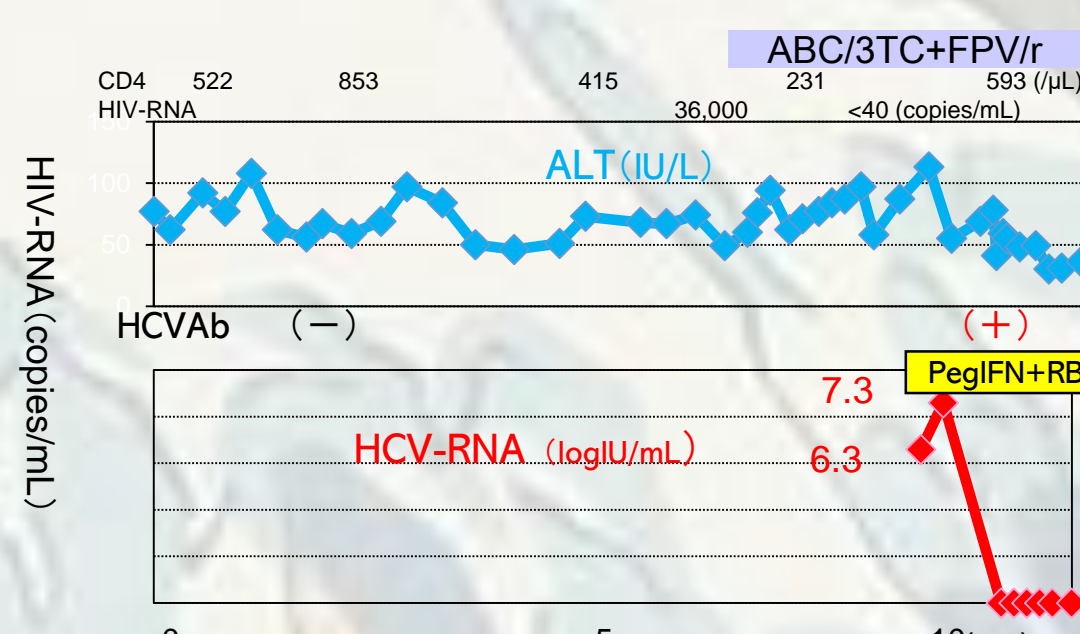
#### Case 4 Hepatitis B co-infection

Chronic HBV infection was diagnosed and started entecavir  
Without testing HIV, NRTI mutations (T215E, M184V(M), V179I) were detected

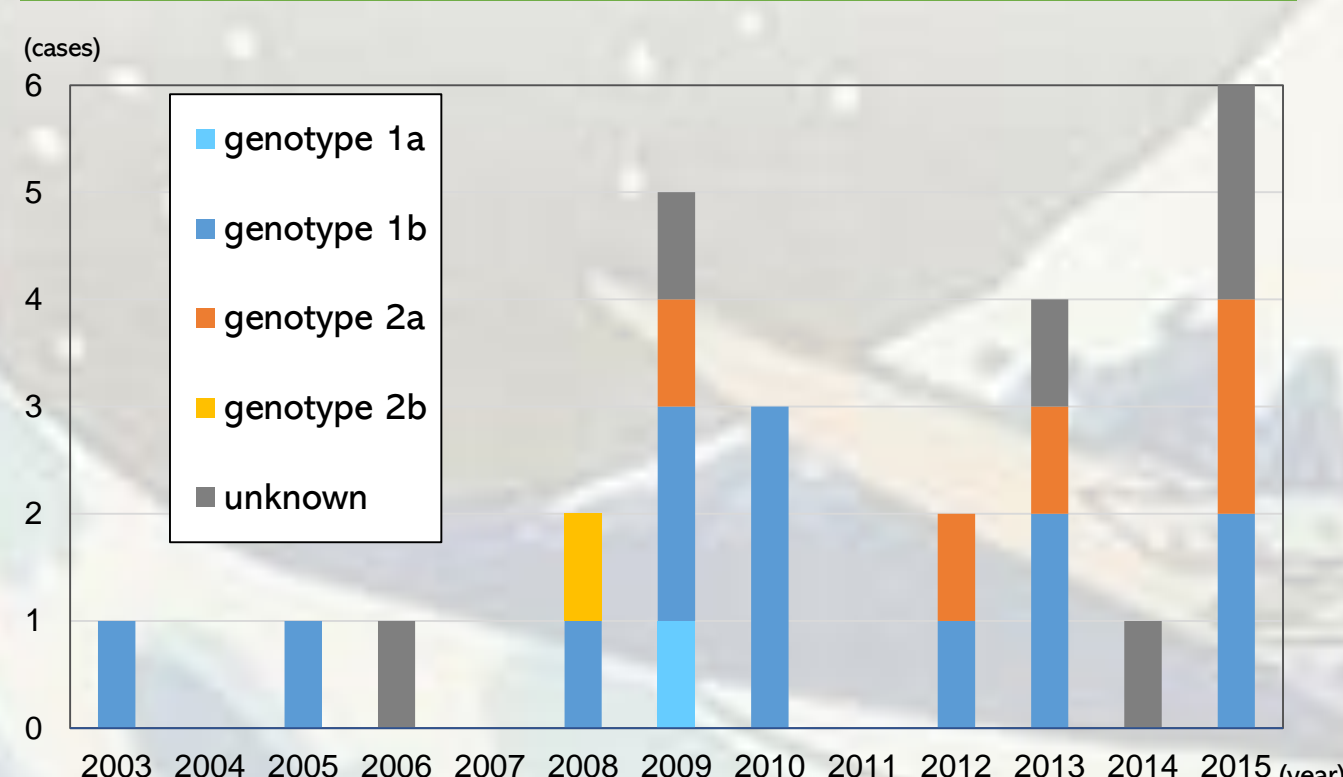


#### Case 5 Hepatitis C

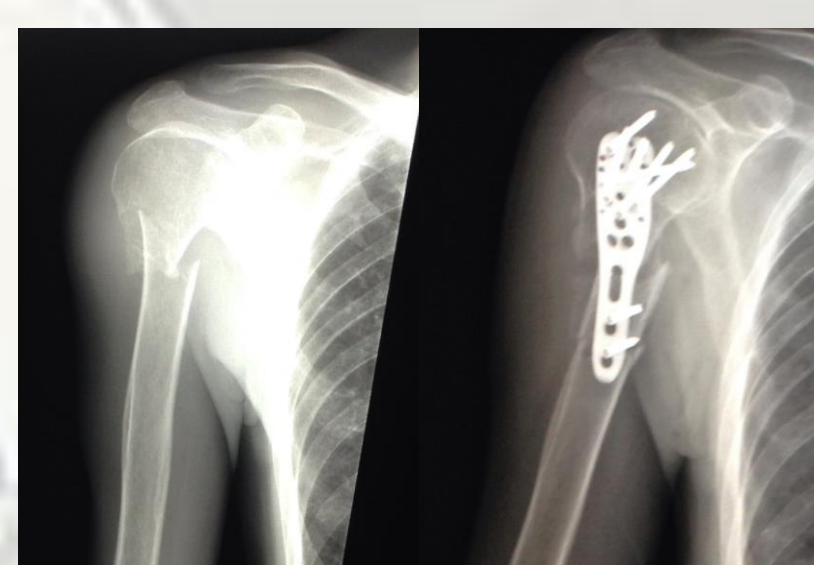43 yo man, diagnosed as fatty liver, and negative for HCVAb at the initial screening.



#### Acute HCV infection in TMUH (n=26)



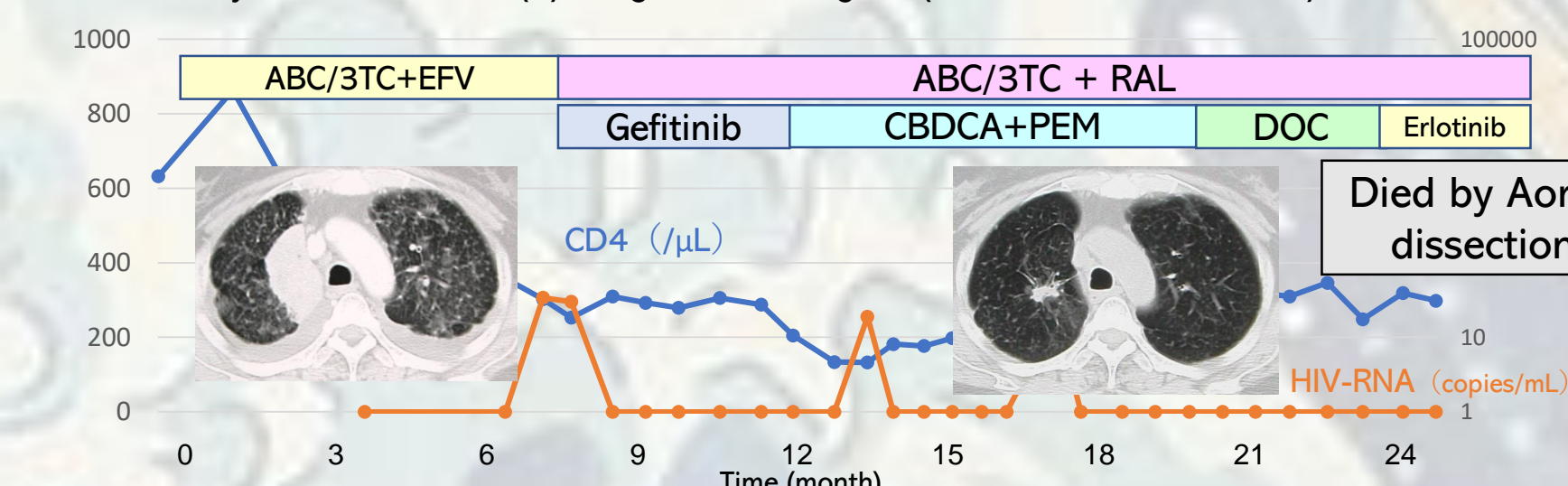
#### Case 6 Multiple fractures



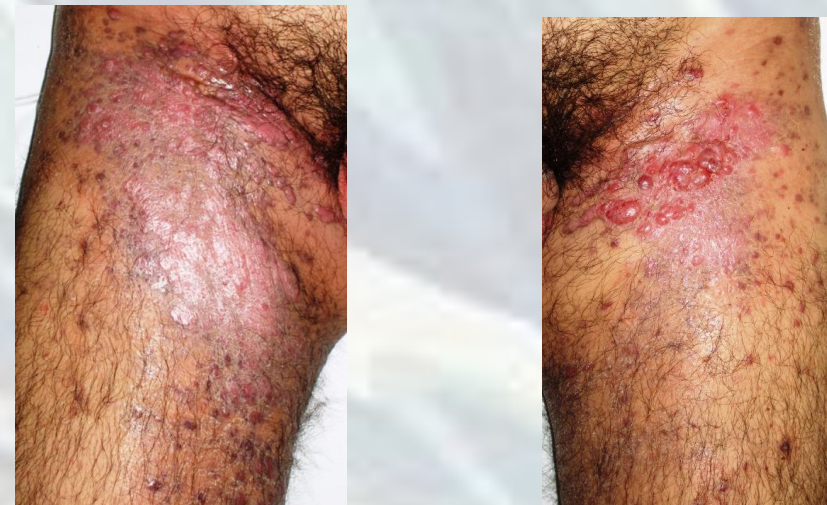
52 yo man, CD4 70/ $\mu$ L, HIV myopathy→multiple falls

#### Case 7 Lung adenocarcinoma

47 yo woman, diabetes(+), Lung adenoCa stage IV (liver and bone metastases)

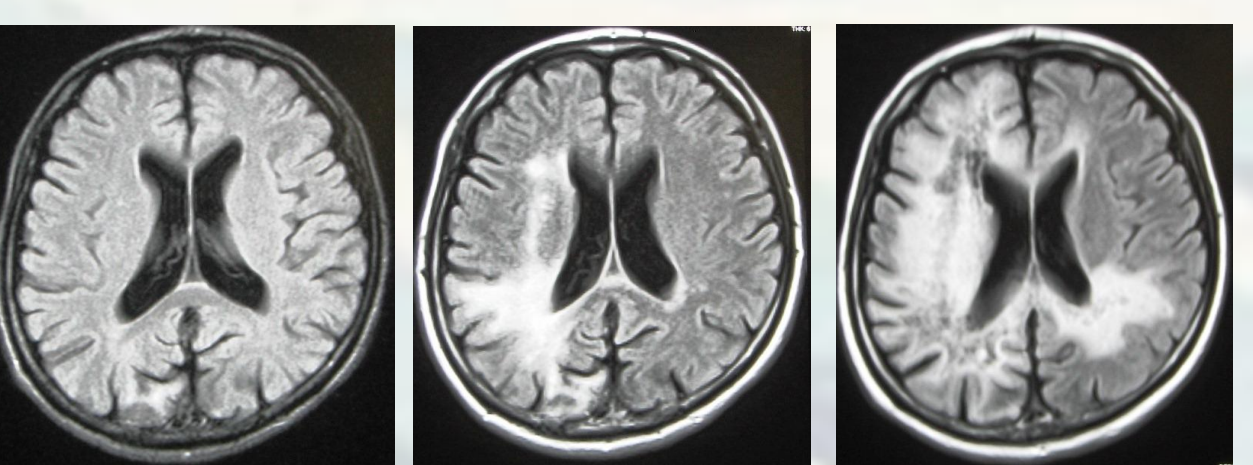


#### Case 8 Kaposi sarcoma



53 yo man  
CD4 >500/ $\mu$ L  
Multiple courses of liposomal doxorubicin

#### Case 9 NeuroAIDS



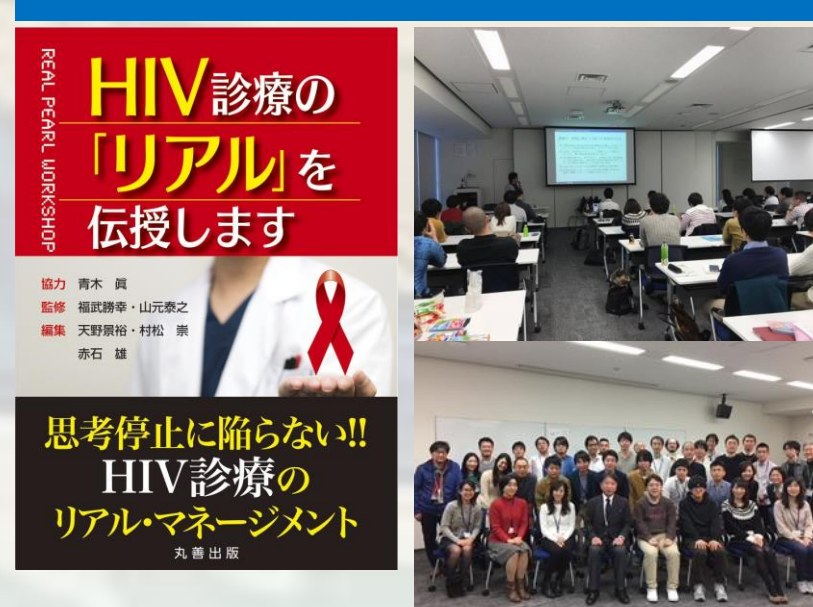
45 yo man  
CD4 71/ $\mu$ L, CSF JCV-DNA positive→PML  
After the start of ART, IRIS against PML started

### Strategies

Early diagnosis, early treatment and prevention

- ✓ Raising awareness among patients and doctors
- ✓ TasP
- ✓ PrEP (clinical trial)
- ✓ Early diagnosis and treatment of STIs, vaccination
- ✓ Long-term complications and aging care

### Our activities and future



- ✓ Seminar for young physicians
  - ✓ Annually, from 2009
  - ✓ 20-30 participants
- ✓ Publication of the seminar
- ✓ Further education is needed